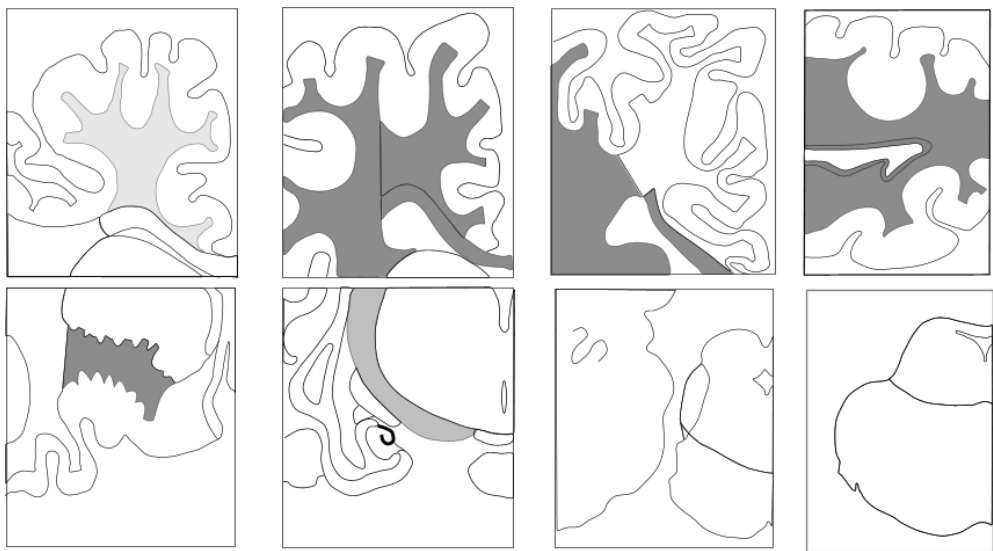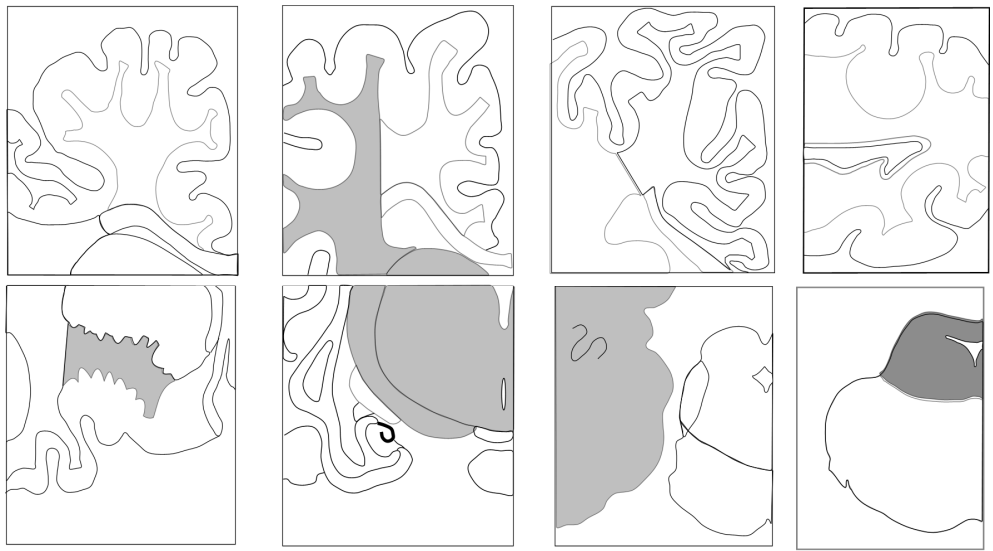
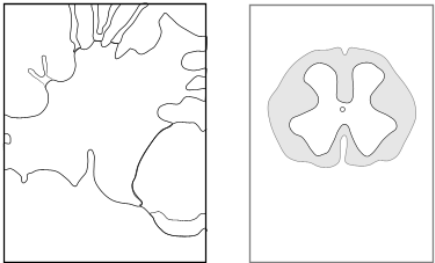


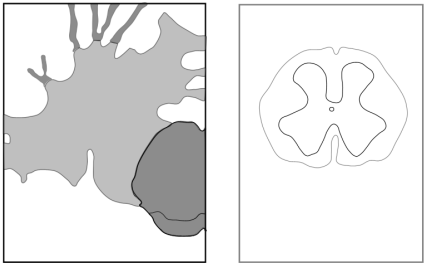
E07/08-20Ph

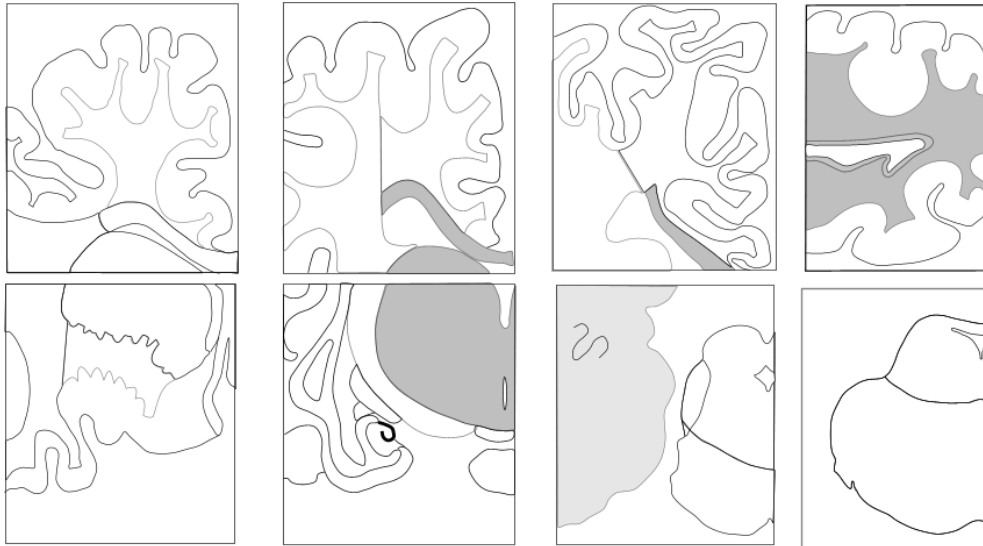
VASCULAR
infectious (septicaemia)
no SDH, no meningitis



E07/08-21Ph

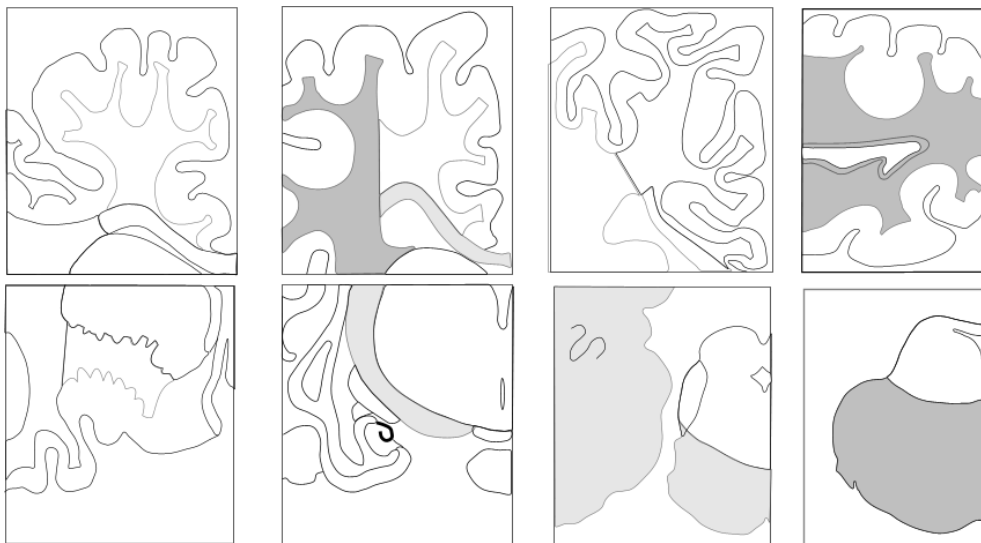
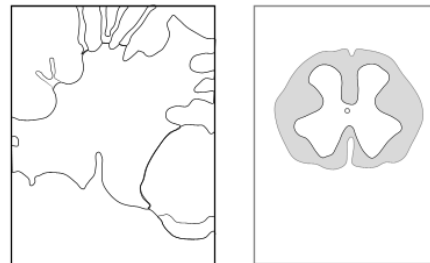
MULTIFOCAL/DIFFUSE
starvation
sp SDH, no meningitis





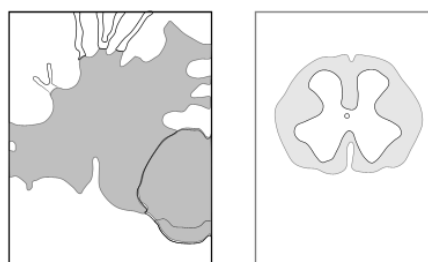
E07/08-22 Ph

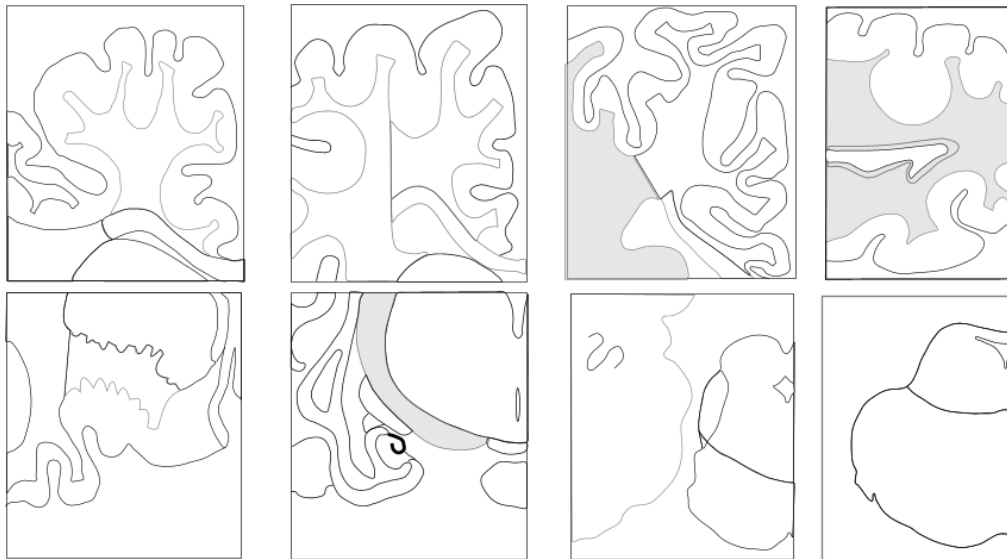
MULTIFOCAL
PERIVENTRICULAR (+ occipital)
PERINEURONAL
trauma (?shake) + starvation
no SDH, no meningitis
skull # (orbit) severe head and neck bruising



E07/08-23Ph

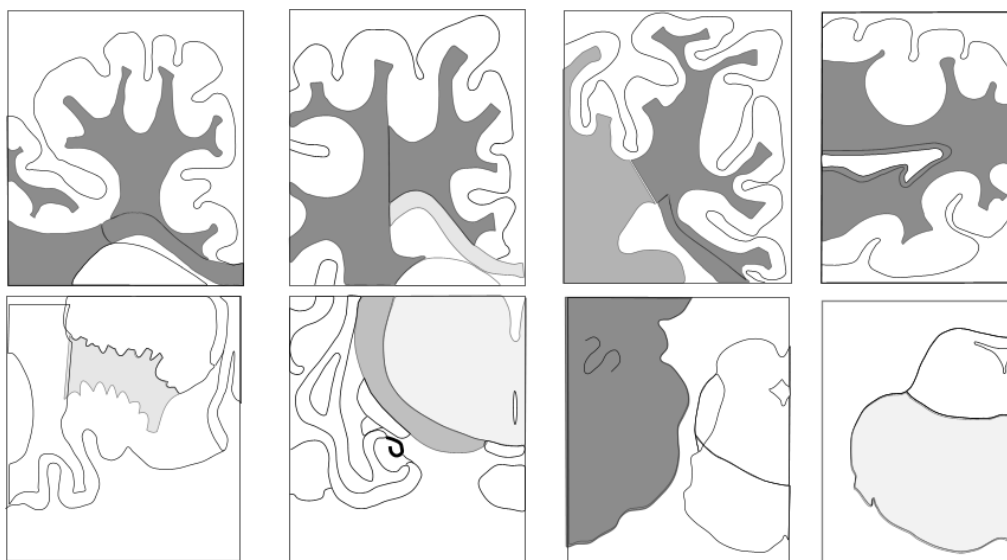
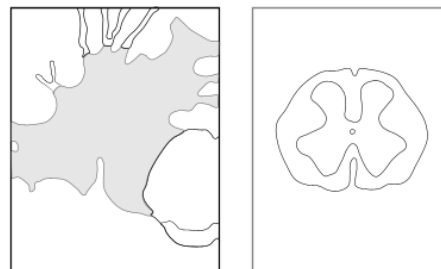
MULTIFOCAL
infectious
sp and cr SDH, meningitis, vermis haem





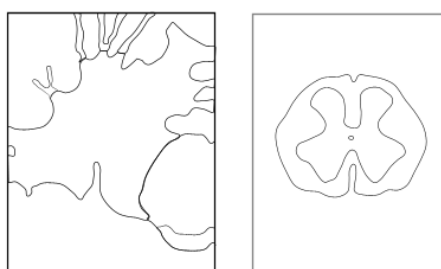
E07/08-24Ph

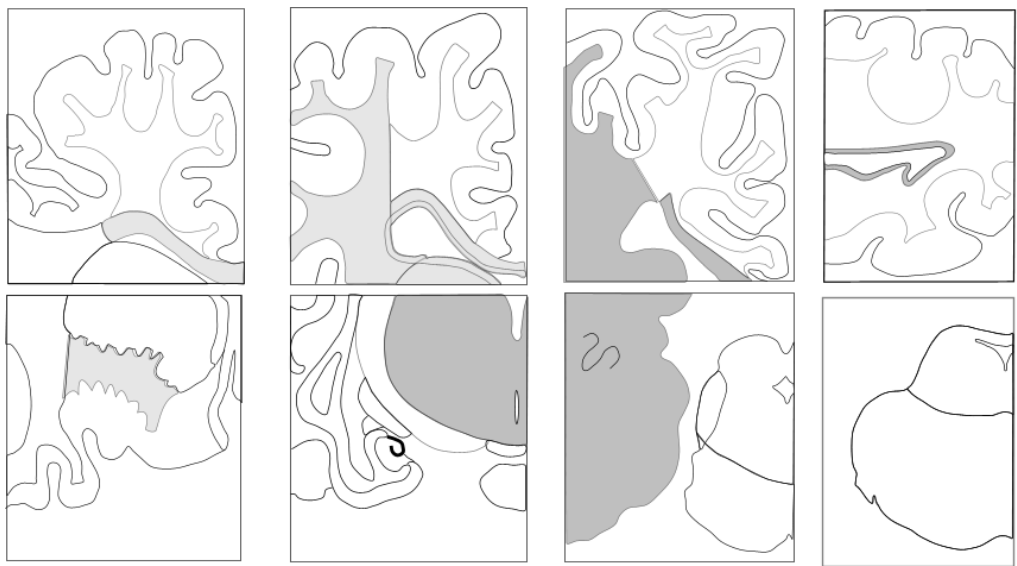
MULTIFOCAL
infectious
no SDH, 'early' meningitis



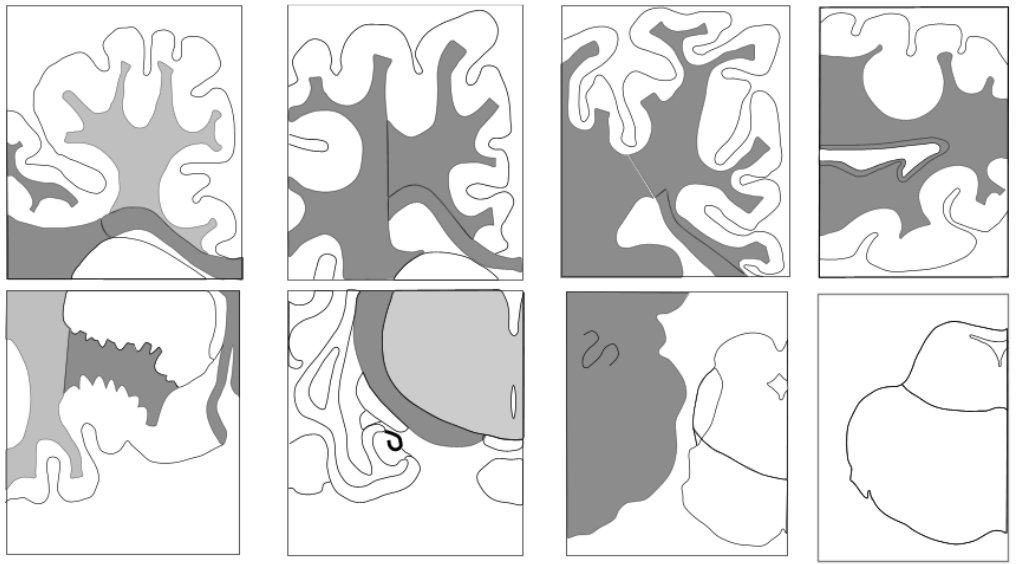
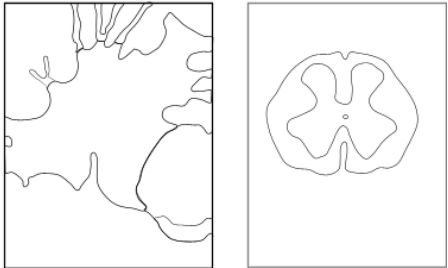
E07/08-25 Ph

VASCULAR
scavenged + hookworm
sp SDH, no meningitis, severe head bruising

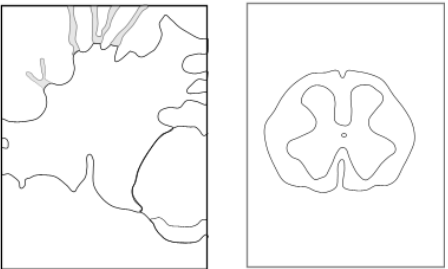


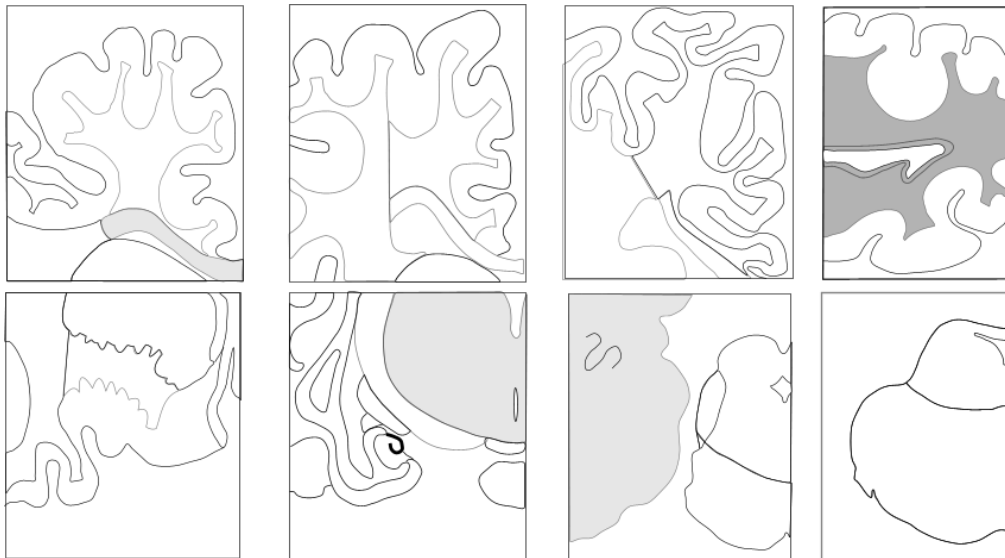


E07/08-26Ph
MULTIFOCAL
PERIVENTRICULAR
hookworm
no SDH, no meningitis



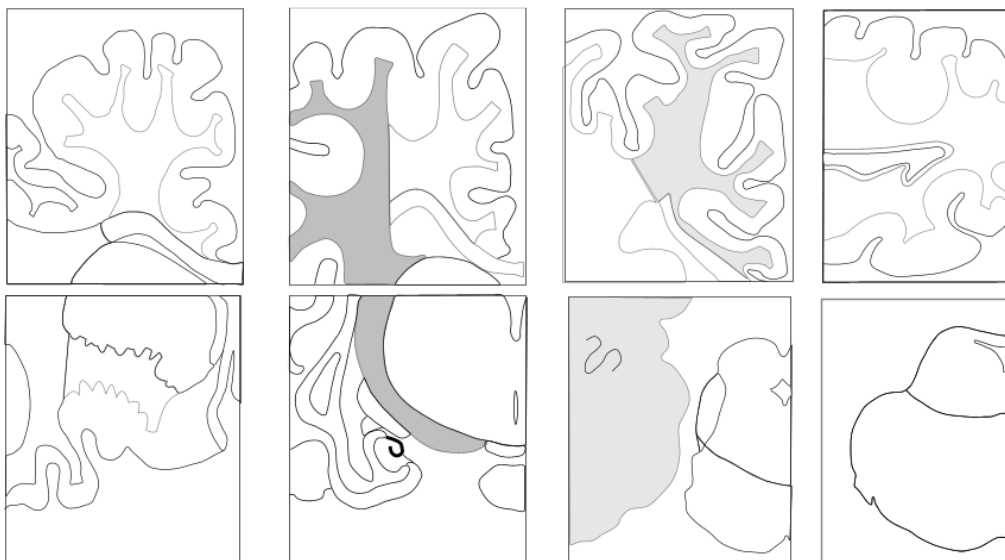
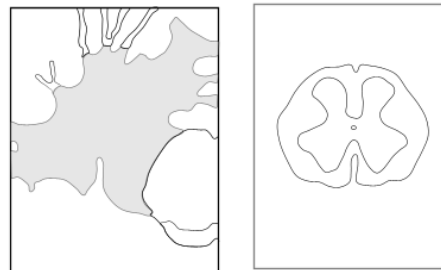
E07/08-27Ph
VASCULAR
scavenged
no SDH, no meningitis





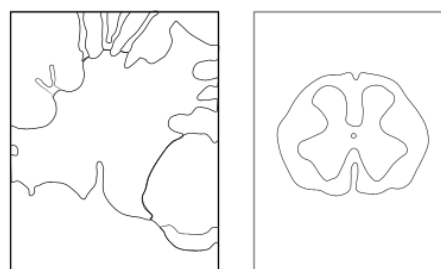
E07/08-28 Ph

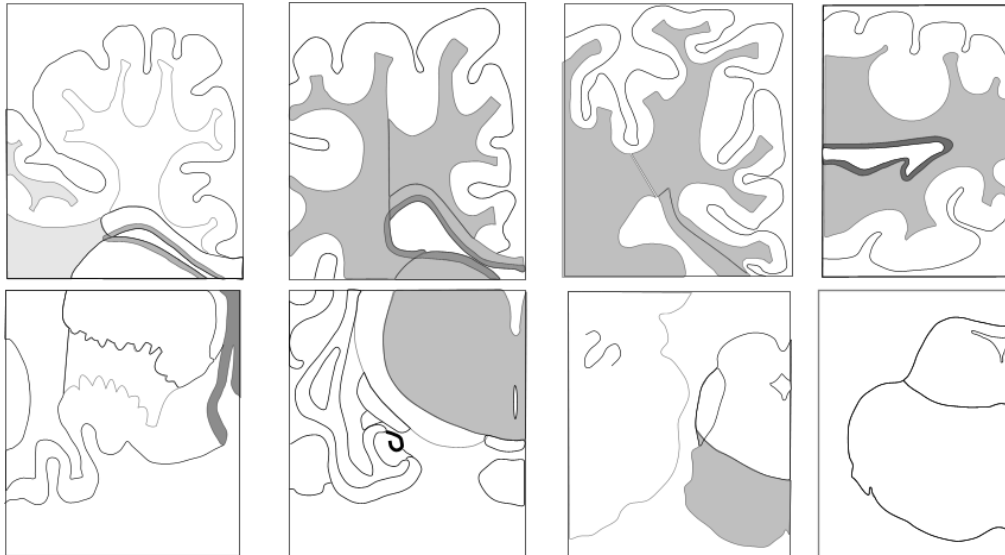
MULTIFOCAL
infectious
no SDH, 'early' meningitis



E07/08-29Ph

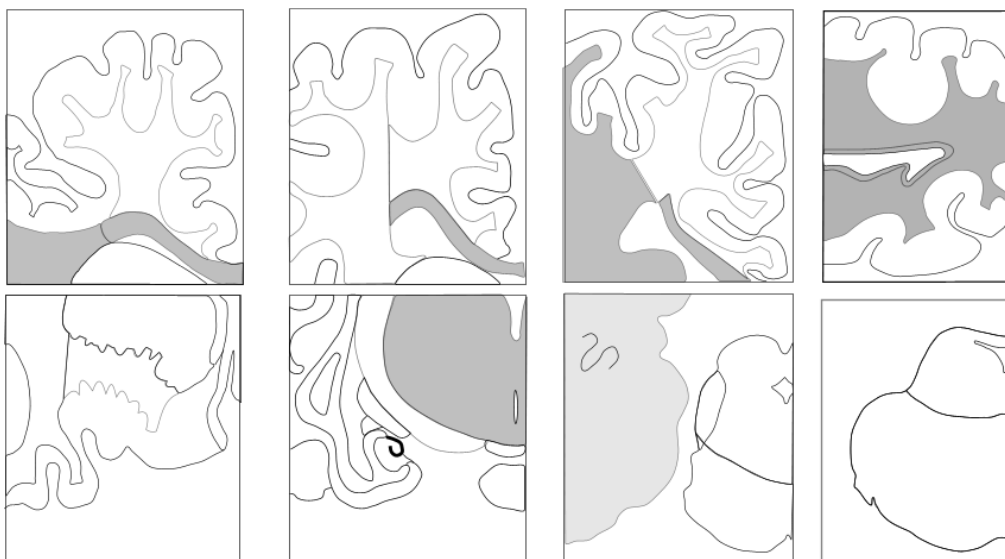
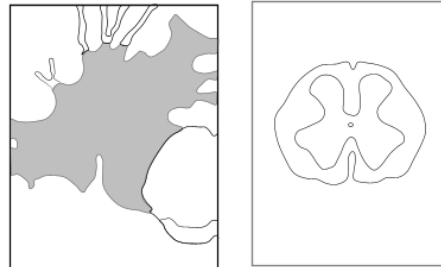
MULTIFOCAL
hookworm + infection
no SDH, 'early' meningitis





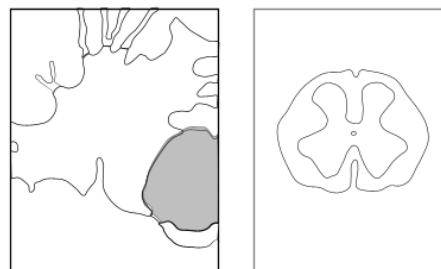
E07/08-30Ph


PERIVENTRICULAR
PENUMBRAL
MULTIFOCAL
infectious (skull bite + abscess + meningitis)
no SDH



E07/08-31Ph

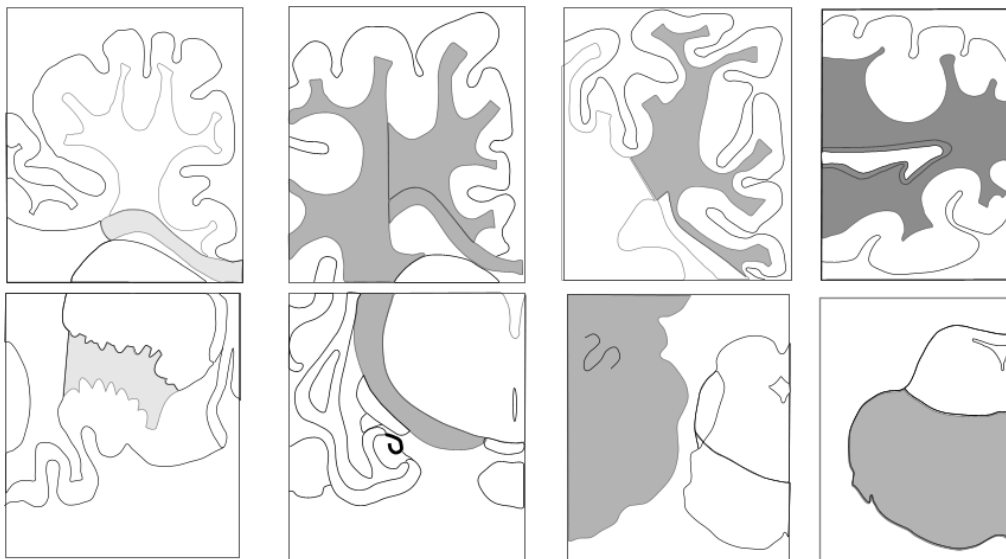
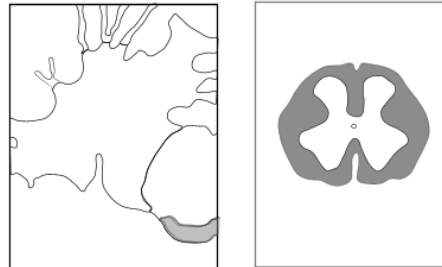
VASCULAR
MULTIFOCAL
infectious + hookworm
meningitis, no SDH





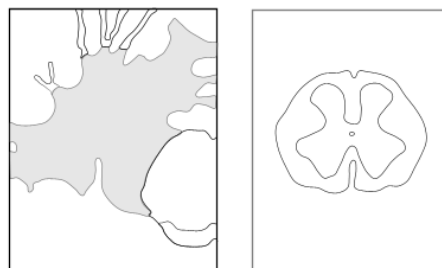
E07/08-32Ph

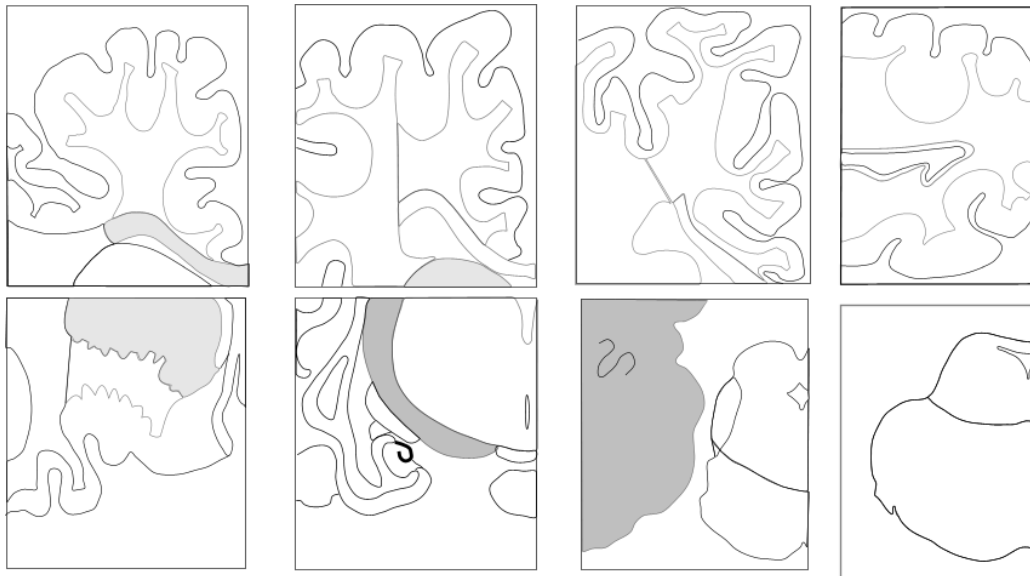
MULTIFOCAL
infection + hookworm
sig head bruising, sp and cr SDH, meningitis



E07/08-33Ph

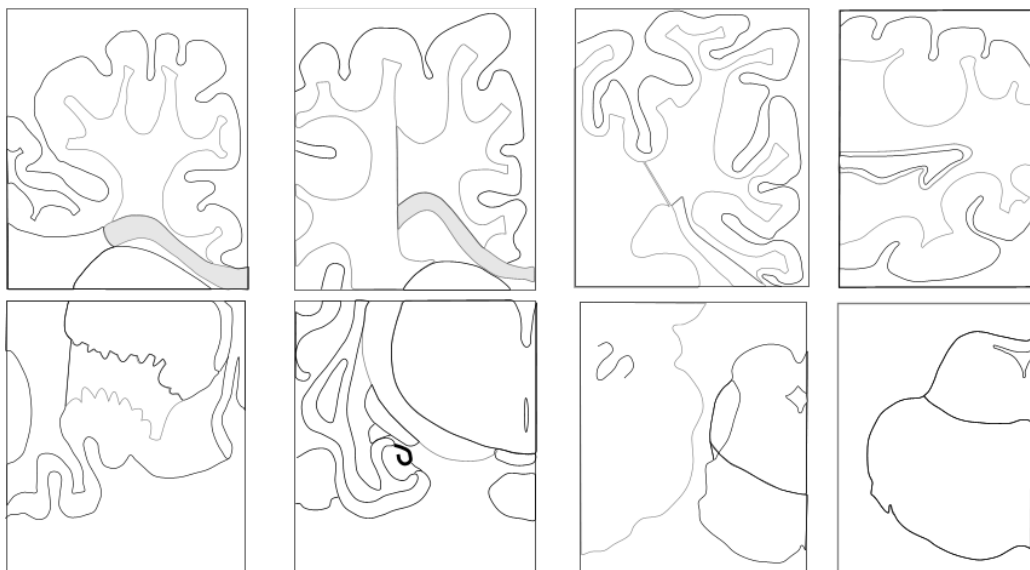
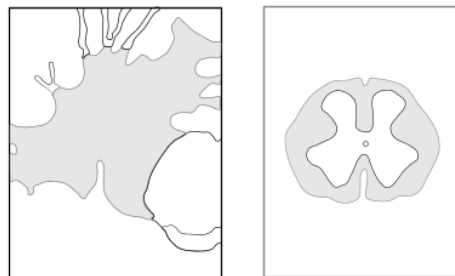
VASCULAR
trauma (crush; abdo)
no SDH, no meningitis





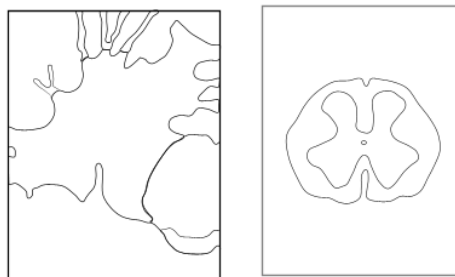
E07/08-34Ph

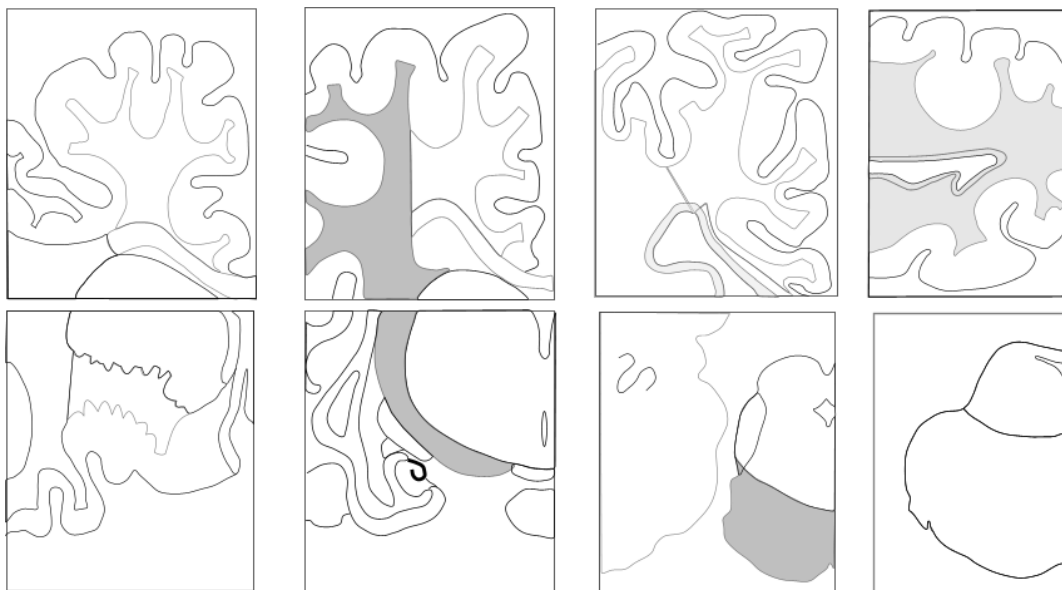
MULTIFOCAL
trauma (shake/impact) + hookworm
sp and cr SDH, sig head bruise, no mening



E07/08-35Ph

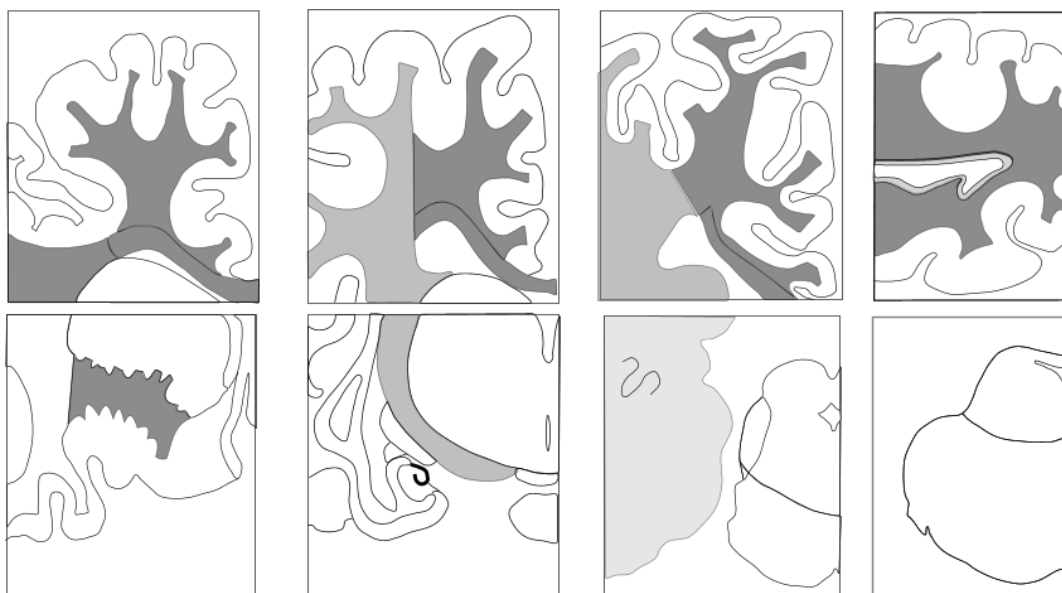
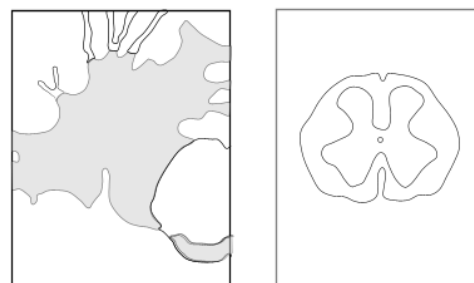
NIL
infectious + hookworm
no SDH, no meningitis





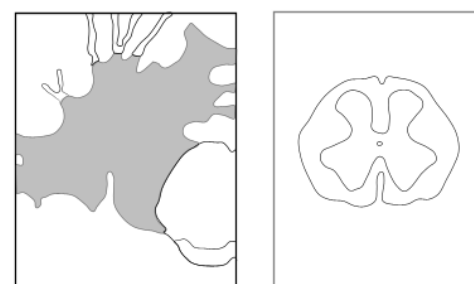
E07/08-36Ph


MULTIFOCAL
PENUMBRAL
PERIVENTRICULAR
infectious
sp and cr SDH, meningitis, vermis haem



E07/08-37Ph

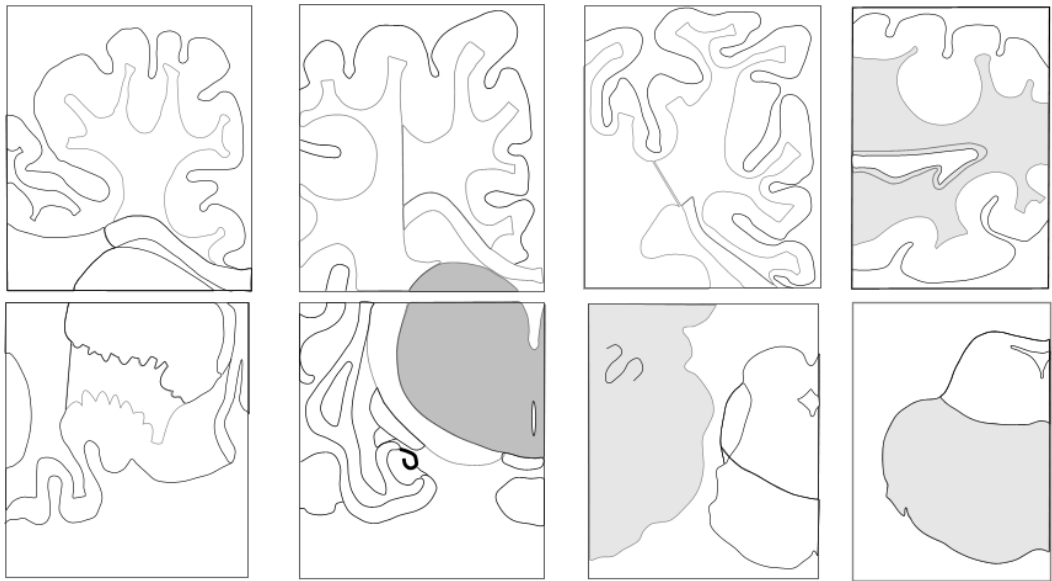
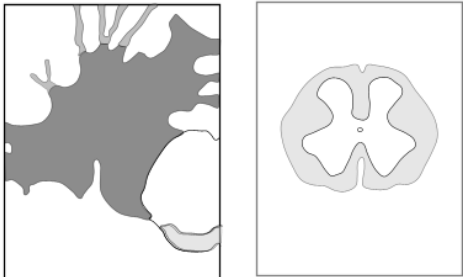
VASCULAR
infectious
meningitis, no SDH





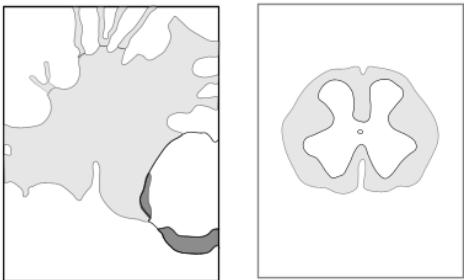
E07/08-38Ph

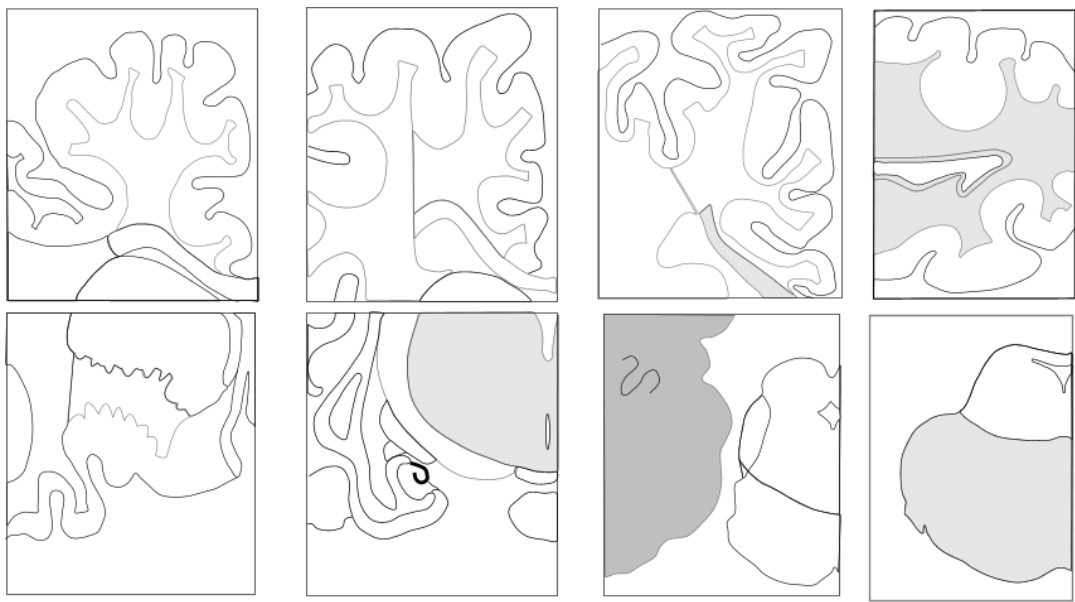
MULTIFOCAL
FOCAL VASCULAR PATTERN (cerebellar peduncle)
infectious
meningitis, no SDH



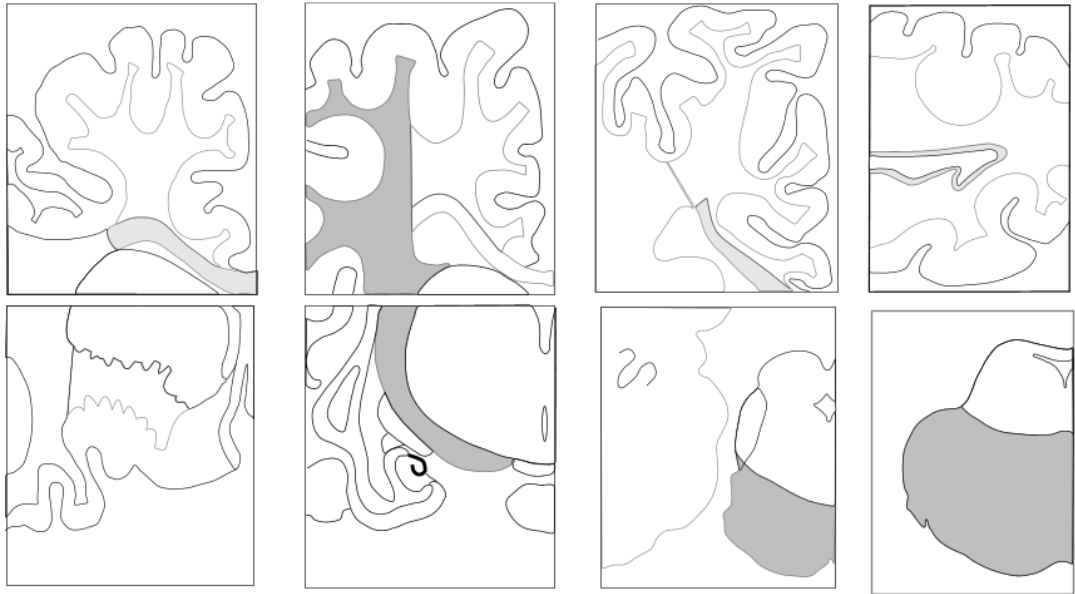
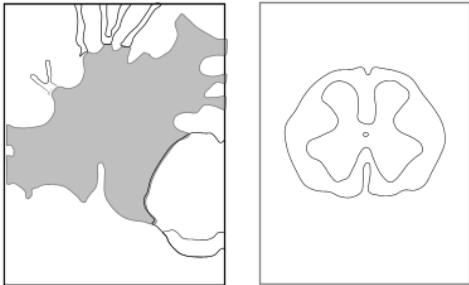
E07/08-39Ph

MULTIFOCAL
PERINEURONAL
infectious
sp and cr SDH, vermis haem, meningitis

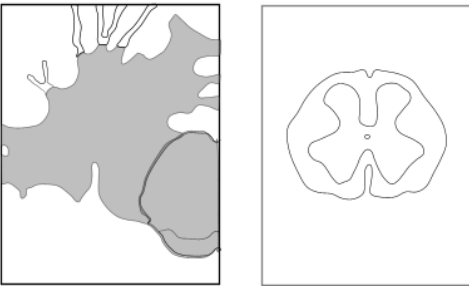





E07/08-40Ph
MULTIFOCAL
infectious
sp SDH, vermis haem, meningitis



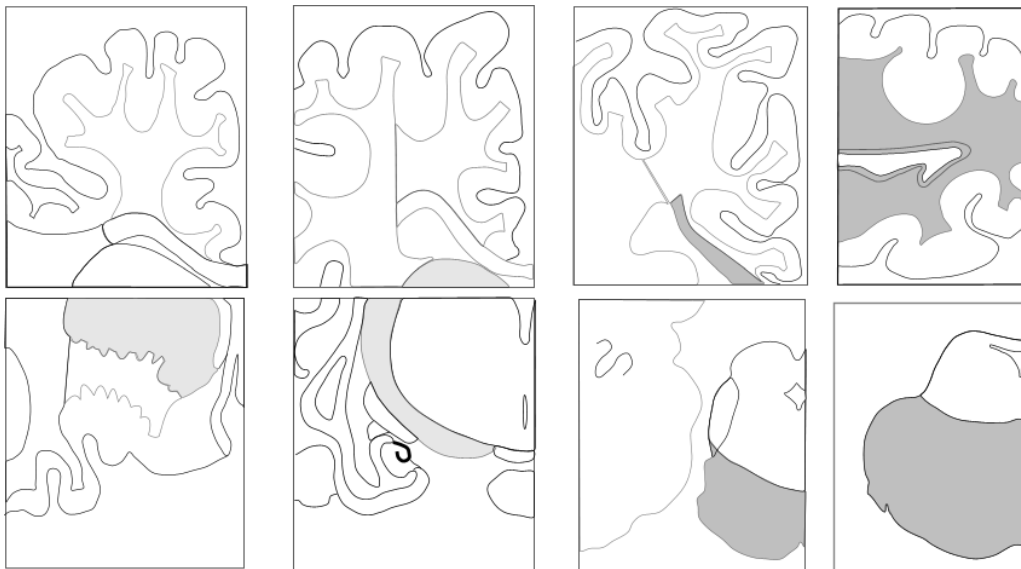
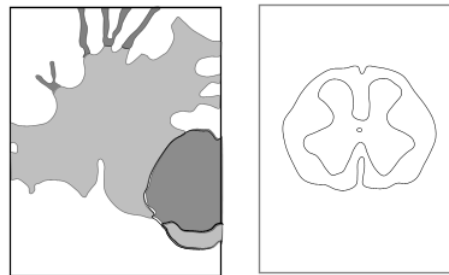
E07/08-41Ph
MULTIFOCAL
PERIVENTRICULAR (occ)
infectious
sp SDH, vermis haem, meningitis





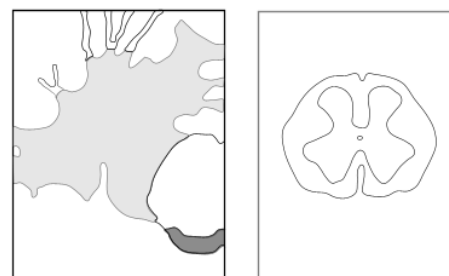
E07/08-42Ph

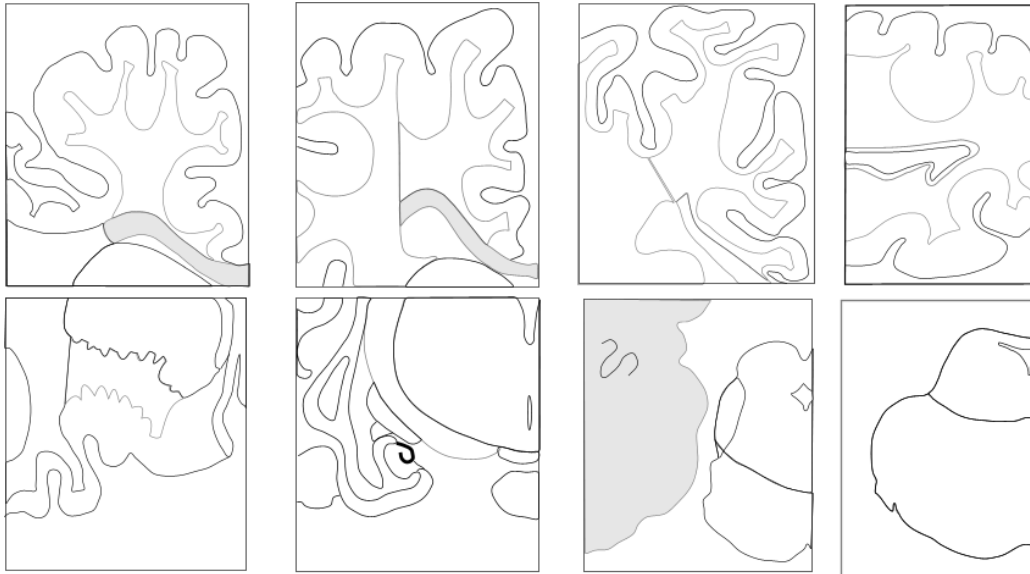
MULTIFOCAL/DIFFUSE (esp cerebellum)
trauma
sp + cr SDH, no meningitis



E07/08-43Ph


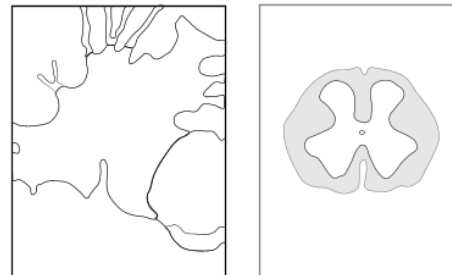
MULTIFOCAL
infectious
sp + cr SDH, meningitis





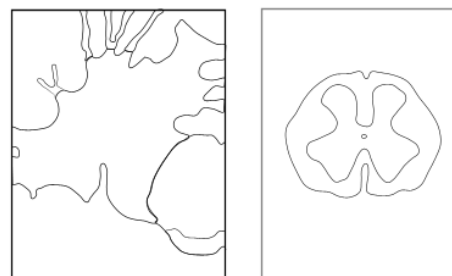
E07/08-44Ph


NEGLIGIBLE
open (autolysed)
epidural sp haem, no meningitis



E07/08-45Ph


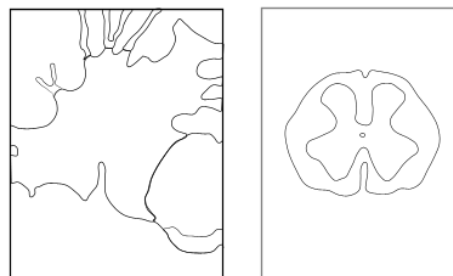
NEGLIGIBLE
infectious
cr SDH + epidural sp





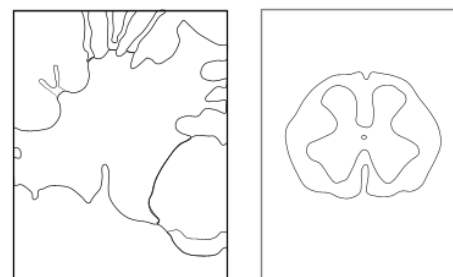
E07/08-48Ph

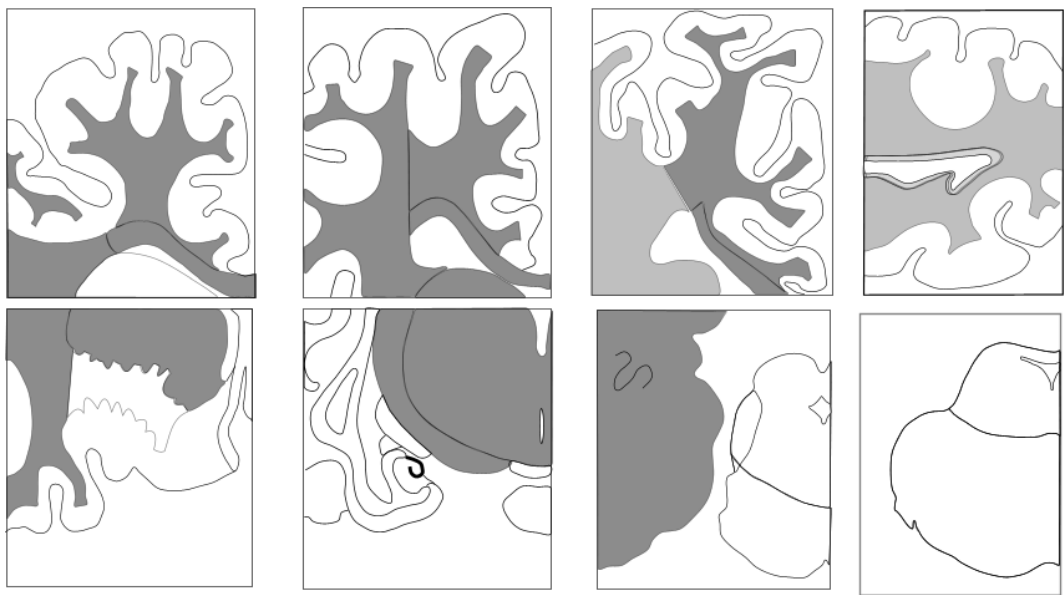
NEGLIGIBLE
infectious
'early' meningitis



E07/08-49Ph

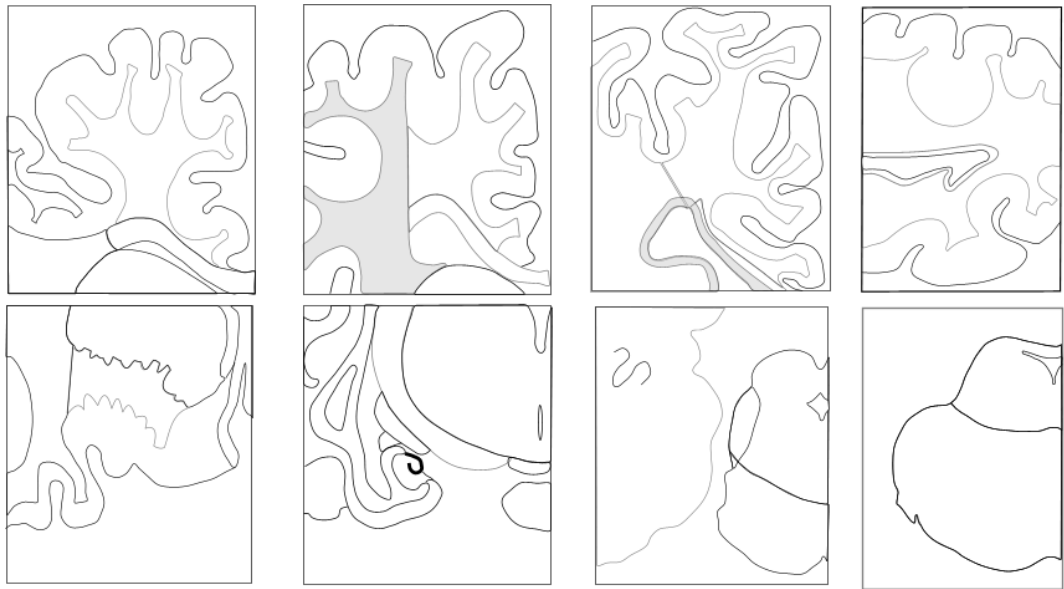
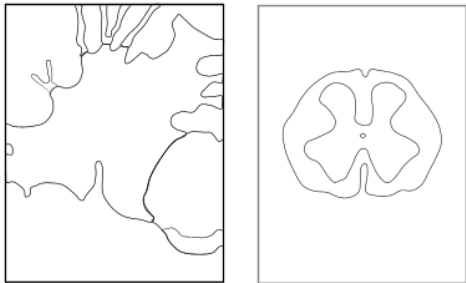
PERIVENTRICULAR
infectious
sp + cr SDH, vermis haem, meningitis





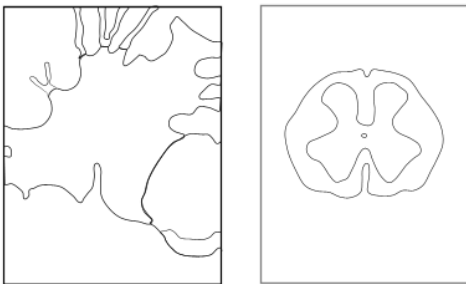E07/08-50Ph


VASCULAR
infectious + hookworm
no SDH, no meningitis



E07/08-51Ph

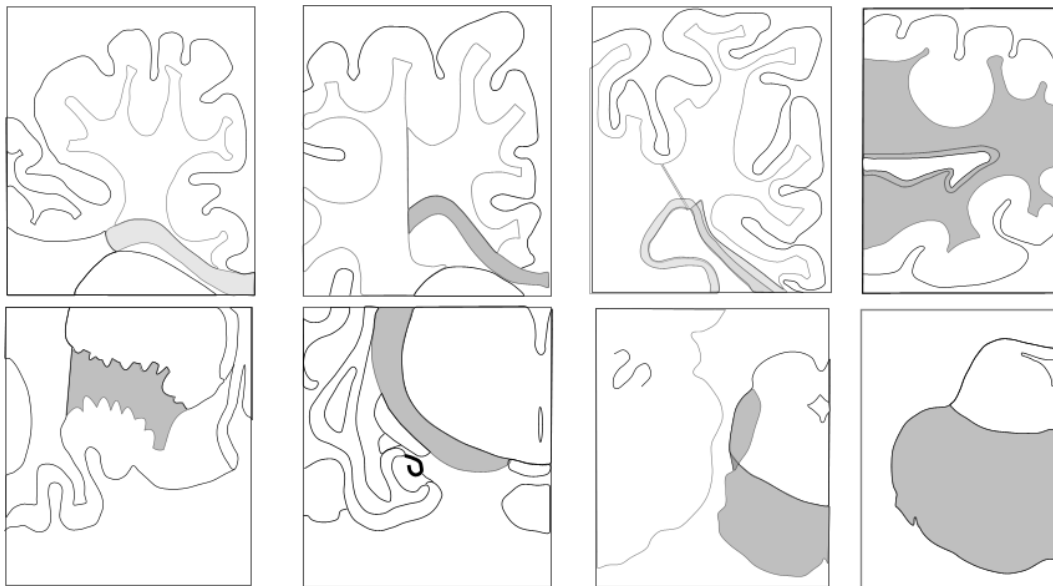
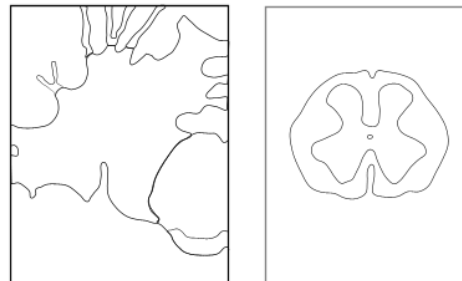
PERIVENTRICULAR
infectious
no SDH, no meningitis





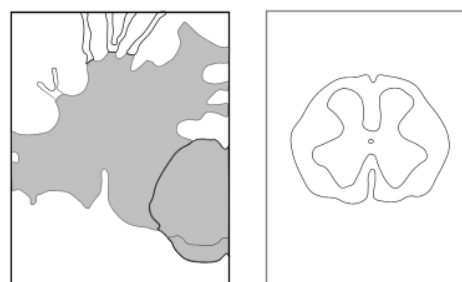
E07/08-52Ph


NEGLIGIBLE
infectious
no SDH, no meningitis



E07/08-53Ph


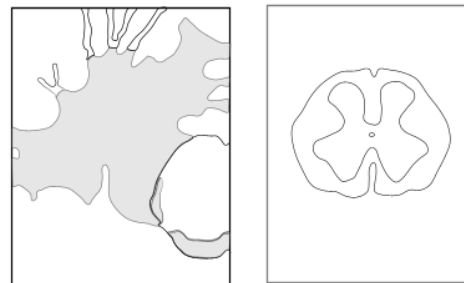
MULTIFOCAL
PERIVENTRICULAR
infectious
sp SDH, vermis haem, meningitis





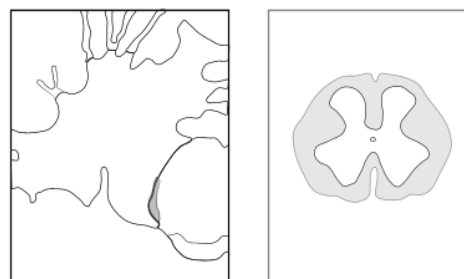
E07/08-54Ph


MULTIFOCAL
infectious
sp + cr SDH, vermis haem, meningitis



E07/08-55Ph


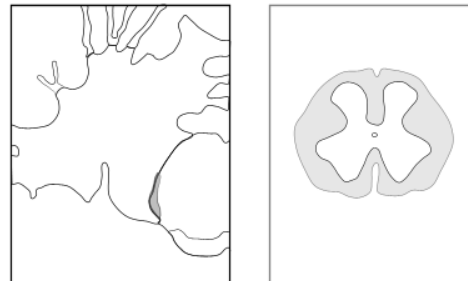
MULTIFOCAL
infectious
sp SDH, meningitis





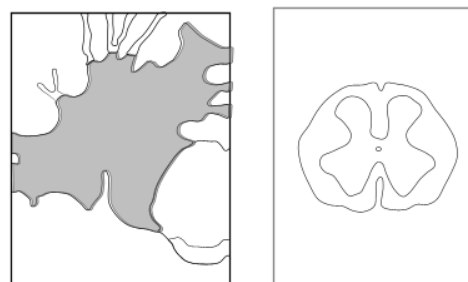
E07/08-55Ph


MULTIFOCAL
infectious
sp SDH, meningitis



E07/08-56Ph

MULTIFOCAL/DIFFUSE
infectious
sp + cr SDH, vermis haem, meningitis





E07/08-57Ph

NEGLIGIBLE
hookworm
no SDH, no meningitis

